

# The Effect of Pulsed Electromagnetic Fields on Secondary Skin Wound Healing: An Experimental Study

Athanasios Athanasiou,<sup>1\*</sup> Spiridon Karkambounas,<sup>1</sup> Anna Batistatou,<sup>2</sup> Efstathios Lykoudis,<sup>3</sup> Afroditi Katsaraki,<sup>4</sup> Theodora Kartsioni,<sup>1</sup> Apostolos Papalois,<sup>5</sup> and Angelos Evangelou<sup>1</sup>

<sup>1</sup>Laboratory of Experimental Physiology, Ioannina University School of Medicine, Greece

<sup>2</sup>Laboratory of Pathology and Anatomy, Ioannina University School of Medicine, Greece

<sup>3</sup>Department of Plastic Surgery and Burns, Ioannina University School of Medicine, Greece

<sup>4</sup>Ioannina University Statistics Service, Athens, Greece

<sup>5</sup>Experimental-Research Unit ELPEN Pharma, Athens, Greece

A variety of pulsed electromagnetic fields (PEMFs) have already been experimentally used, in an effort to promote wound healing. The aim of the present study was to investigate the effects of short duration PEMF on secondary healing of full thickness skin wounds in a rat model. Full thickness skin wounds, 2 by 2 cm, were surgically inflicted in two groups of male Wistar rats, 24 animals each. In the first group (experimental group - EG), the animals were placed and immobilized in a special constructed cage. Then the animals were exposed to a short duration PEMF for 20 min daily. In the second group (control group - CG), the animals were also placed and immobilized in the same cage for the same time, but not exposed to PEMF. On days 3, 6, 9, 12, 18, and 22, following the infliction of skin wounds, the size and healing progress of each wound were recorded and evaluated by means of planimetry and histological examination. According to our findings with the planimetry, there was a statistically significant acceleration of the healing rate for the first 9 days in EG, whereas a qualitative improvement of healing progress was identified by histological examination at all time points, compared to the control group. *Bioelectromagnetics* 28:362–368, 2007. © 2007 Wiley-Liss, Inc.

**Key words:** PEMF; secondary healing; skin wounds; rats; magnetic pulse

## INTRODUCTION

In the last three decades, a large number of studies have proved that EMFs have multiple effects to living organisms [Aaron and Ciombor, 1993; Walker et al., 1994; Tao and Henderson, 1999; Tofani et al., 2002]. These effects mainly refer to alteration of the cell-proliferation rate, changes in the levels of mRNA and protein synthesis, alteration of cellular membrane's permeability, and Ca<sup>2+</sup>, Na<sup>+</sup>, K<sup>+</sup> ion transfer. All the above lead to alterations of both the electrical and metabolic behavior of cells, influence the differentiation of primitive stem cells, and alter the rates of apoptosis in both normal and neoplastic cells [Walker et al., 1994; Han et al., 1998; Tao et al., 1999; Islamov et al., 2002; Tofani et al., 2002; Stonati et al., 2004]. Additionally, it seems that EMFs have a direct or indirect action, on the production of melatonin by epiphysis cerebri (pineal gland), resulting in the emergence of disorders of the organism's circadian and hormone production rhythms [Reiter, 1993]. Furthermore, it is obvious that EMFs of certain

frequencies and intensities alter the behavior of T-lymphocytes, as far as their cytotoxicity is concerned [Albinucci et al., 2003a,b; Murabayashi et al., 2004]. At a molecular level, fields influence the expression of early-induced genes such as c-myc, c-fos, c-jun, and they affect synthesis of various proteins, among them, the tumor suppressor protein P53 [Tofani et al., 2002]. There are certain studies indicating that EMFs can operate as carcinogenesis-promoting factors, after pro-administration of benzo [a] pyrene [Simko et al., 2001],

Grant sponsor: ELPEN Pharma.

\*Correspondence to: Dr. Athanasios Athanasiou, Department of Physiology, Ioannina University School of Medicine, Marathononmaxon 15-17, 151.24 Athens, Greece. E-mail: tanasisa@yahoo.gr

Received for review 10 November 2005; Final revision received 31 August 2006

DOI 10.1002/bem.20303

Published online 7 May 2007 in Wiley InterScience (www.interscience.wiley.com).

while other studies show that EMFs have the ability to significantly inhibit the tumor growth in athymic mice and other neoplastic diseases models [Tofani et al., 2001, 2002]. The biological actions of EMFs on the organisms seem to be due to their ability to induce changes, both in cells (temperature increase and expression of heat shock proteins) and in other signal transduction systems of the cells, especially focused on the intermediates that bear the characteristics of free radicals [Sciano et al., 1994; Walleczek, 1995; Lander, 1997].

There are different theories that may explain the effects of EMFs on the biological targets and especially on the procedure of tissue regeneration and cell proliferation. Those theories seem to merge to the following common theoretical framework. Pulsed electromagnetic fields (PEMFs) are capable in altering the structure of the cell membranes and thus diversify the permeability of different ion channels and the potential of the cellular membranes. Both phenomena are important of cellular functions [Blackman et al., 1980; Walleczek and Liburdy, 1990; Ikehara et al., 2002], such as the production of chemical energy in the form of adenosine triphosphate (ATP) and the variance of intracellular free calcium levels, which is a second type universal intermediate ion [Carafoli, 2004]. They may also conserve the normal electrochemical gradient of cells, a necessary condition for ATP production, which may be lowered by ischemia or trauma. Thus, they might ensure a high performance and elevated protein synthesis (anabolic reactions) of cells [Westerhoff et al., 1983]. Other theories suggest that the primary actions of EMFs are correlated with the production of small quantities of free radicals within cells. These radicals can function as mediator molecules on the systems of intracellular communication [Scaiano et al., 1994; Lander, 1997].

In the current study, a powerful short duration PEMF, produced by a specialized device, was used, in order to evaluate its effects on the healing process of surgically created skin wounds in a rat model. The main advantage of the field produced is that short duration electromagnetic pulses protect the biological targets from the development of increased temperatures.

## MATERIALS AND METHODS

Forty-eight male Wistar rats, 4 months old and weighting  $200 \pm 30$  g, were used. All experimental procedures were approved by the animal care committee of the local veterinary directorate and cared for, according to the Greek and European guidelines, regulating animal research. The rats were acclimated for a period of 3 days prior to experimentation, during

which they were examined for any signs of disease. Throughout the entire study period, the animals were kept under stable conditions (temperature  $22^{\circ}\text{C}$ , humidity 30–70%, light cycles on 12/12 h light/dark schedule), and nourished with dried pellets and tap water.

All animals, following intraperitoneal anesthesia (Ketamine 3.5 mg/kg B.W and Midazolamin 7 mg/kg B.W), underwent en block excision of the skin and underlying panniculus carnosus of a square shaped area, measuring 2 by 2 cm from their back (day 0) (Fig. 1). Post-surgically, the rats were returned to their cages and housed individually, in order to avoid cannibalistic behavior. Dressings were not used and antibiotics were not administered.

From day 0 and on a daily basis, all rats were placed and immobilized for 20 min in specially constructed wooden cages, sized  $32 \times 16$  cm, and divided into four chambers. The dimensions of each chamber ( $16 \times 8$  cm) were small enough to keep the animals restrained. No metallic components were used, in order to avoid any interference with the electromagnetic field. The antenna loop ( $30 \times 15$  cm, one winding with two turns) of a device, producing a short duration bipolar PEMF producing was horizontally centered over the cage, at a distance of 5 cm from the wound surface (PAPIMI model 600, Pulse Dynamics, Athens, Greece. Manufacturer characteristics: 35–80 J/pulse energy,  $1 \times 10^{-6}$  s wave duration,  $35\text{--}80 \times 10^6$  W wave power, amplitude on the order of 12.5 mT, rise time 0.1  $\mu\text{s}$ , fall time 10  $\mu\text{s}$ , repetitive frequency of 3 Hz.). The position of the animals in the chambers was symmetric and equidistant from the perimeter of the loop.

The rats were randomized in two groups of 24 each. In the first group (experimental - EG), the

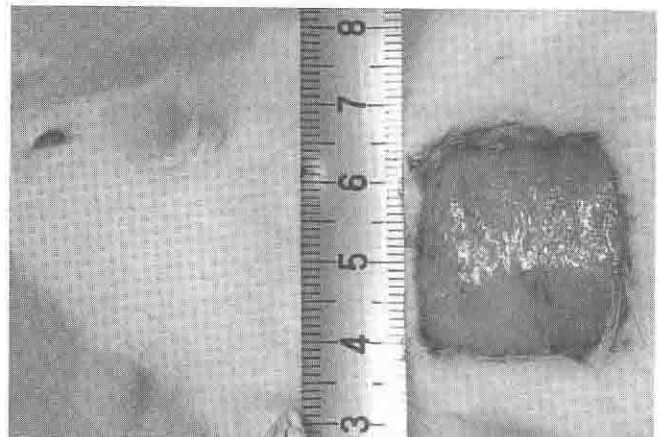


Fig. 1. A square shaped area ( $2 \times 2$  cm), excised from the dorsum of the animal. [The color figure for this article is available online at [www.interscience.wiley.com](http://www.interscience.wiley.com).]

animals were exposed to the PEMF, while in the second group (control - CG), although the animals were caged for the same time, the device was not activated.

On days 3, 6, 9, 12, 18, and 22 after wound creation, four rats of each group were sacrificed, in order to evaluate the healing process. The wounds were photographed with a digital camera (SONY P-10, Japan). Also, the size of each wound, including the crust, was measured with the use of a high precision ( $1 \text{ mm}^2$ ) polar planimeter (HAFF planimeters, model N° 317 E, W, West Germany, Germany) after tracing of its borders on plastic film. Finally, tissue specimens were harvested for histological examination. All specimens were fixed in 10% formalin solution, paraffin-embedded, cut in  $4 \mu\text{m}$  thick sections perpendicularly to the skin surface, including the whole thickness of the skin wound and the surrounding healthy tissue, and stained with hematoxylin-eosin.

Given that in both groups, wound healing was anticipated by the end of the experiment, the following parameters were qualitatively evaluated as a sequence of events, starting from Stage 1 (blood clot) and ending with Stage 6 (scar formation with complete re-epithelization). The intermediate stages were considered as Stage 2 (immature granulation tissue), Stage 3 (mature granulation tissue), Stage 4 (fibroblasts and collagen fibrils, but not complete re-epithelization yet), Stage 5 (abundant fibroblasts, dense collagen deposition, almost complete re-epithelization).

### Statistical Analysis

The Mann-Whitney statistical analysis test was used to evaluate the significance of differences between groups, accepting 5% ( $P < .05$ ) as the level of significance (Table 1). The significance of the results obtained is supported by histopathological evaluations.

### RESULTS

Throughout the entire experiment, all rats in both groups remained healthy. All wound sites went through the normal wound healing process, with no signs of infection or purulent discharge. The results obtained from the planimetric evaluation of the total wound area, including the crust, on days 3, 6, 9, 12, 18, and 22 after surgery, are listed in Table 1. Statistically significant acceleration of wound healing was noticed in the experimental group compared to the control, on days 3, 6, and 9 ( $P < .02$ ). For the rest of the assessment period, although wound healing was faster in EG, there was no statistically significant difference compared to the CG. The difference between those rates is clearly represented in Figure 2.

TABLE 1. Wound Area Measured by Planimetry

0 Day	Wound healing surfaces ( $\text{cm}^2$ )											
	3 Days		6 Days		9 Days		12 Days		18 days		22 days	
	Mean $\pm$ SD	Median (range)	Mean $\pm$ SD	Median (range)	Mean $\pm$ SD	Median (range)	Mean $\pm$ SD	Median (range)	Mean $\pm$ SD	Median (range)	Mean $\pm$ SD	Median (range)
Experiment group	4.36 (3.84-4.78)	2.7 (2.4-3.1)	2.07 $\pm$ 0.17	2.05 (1.9-2.3)	1 $\pm$ 0.36	1 (0.6-1.4)	0.35 $\pm$ 0.13	0.35 (0.2-0.5)	0.06 $\pm$ 0.05	0.05 (0-0.1)	0.06 $\pm$ 0.05	0.05 (0-0.1)
Control group	4.36 (3.84-4.78)	3.7 (3.2-3.8)	3.05 $\pm$ 0.13	3.05 (2.9-3.2)	1.8 $\pm$ 0.13	1.85 (1.7-2)	0.5 $\pm$ 0.08	0.5 (0.4-0.6)	0.15 $\pm$ 0.13	0.15 (0-0.3)	0.15 $\pm$ 0.13	0.15 (0-0.3)
P		.0201		.0209		.021		.1 (ns)				.22 (ns)

The P-values considered statistical significant when  $P < .05$ .

As for histology evaluation the following findings were recorded:

Day 3: In the control group, the area of the wound was completely covered by blood clot with numerous inflammatory cells. No remarkable granulation tissue was observed (Stage 1). In contrast, in the experimental group underneath the superficial blood clot, a loose connective tissue with edema, polymorphonuclear neutrophils granulocytes, newly formed capillaries, and immature fibroblasts were noted (Stage 2) (Fig. 3a).

Day 6: The histological findings in the control group were comparable to those of the experimental group in Day 3, that is, prominent infiltration by polymorphonuclear neutrophils, loose connective tissue with few capillaries, and stimulated fibroblasts (Stage 2). In the experimental group, there was a significant decrease in the number of acute inflammatory cells. In addition, a denser connective tissue with a clearly developed capillary network and several fibroblasts were noted (Stage 3).

Day 9: Inflammatory cells were no longer observed in the specimens derived from the experimental group. A significant population of mature, flattened, fibroblasts was noted and the capillary network appeared to be denser and more mature. The collagen fibers were increased and formed thick bundles, oriented parallel to the epidermis (Stage 4). In the control group, the histological findings were the same with the ones from the treatment group on day 6 (Stage 3) (Fig. 3b).

Day 12: In the experimental group, scar tissue with almost complete re-epithelialization was observed. In the dermis, a few flattened fibroblasts as well as abundant bundles of collagen, oriented parallel to the surface, were noted (Stage 3). In the control group, there were increased numbers of mature fibroblasts and blood capillaries and the bundles of

collagen were notably thinner. Here also, there was significant re-epithelialization (Stage 4).

Day 18: In the experimental group, an advanced stage of healing was evident. There was almost a complete covering of the wound by keratinocytes forming the epidermis. Underneath, a fibrous connective tissue was noted (Stage 6). In the control group, the squamous epithelial cell layer was noted; however, it consisted of only a few layers of immature keratinocytes (Stage 5) (Fig. 3c).

Day 22: In the experimental group, a complete wound healing was noticed. In the control group, the histological findings were similar to those from the experimental group on day 18.

## DISCUSSION

In the current study, the biological effects of short duration PEMF on secondary wound healing were investigated in a full thickness, surgically created skin defect rat model.

Regarding the effects of electromagnetic fields on tissue repair, there is a great variety of reports in the literature, referring to bone formation, tendon healing, and axonal regeneration, wound healing etc. [Bassett, 1993; Agren et al., 1994; Walker et al., 1994; Ryaby, 1998; Robotti et al., 1999; Macias et al., 2000; Aaron et al., 2004]. As for the effect of PEMF on full thickness skin wound healing, there are fewer reports with controversial findings: (a) Milgram et al. [2004] reported on the use of short duration PEMF for secondary healing of skin wounds in rats. According to their findings, an increase of epithelialization was noticed in the treated group during early stages of wound repair, but there was no statistically significant difference when compared to the control group. (b) In Ottani et al. [1988], an extremely-low-frequency magnetic field was used and a significant increase in the ratio of wound contraction was found in the treated animals. (c) Patino et al. [1996] investigated the effect of PEMF and their results suggested a significant beneficial stimulation in the wound healing process of treated rats.

In our study, the same device as the one by Milgram et al. [2004], was used. The basic differences between the two studies were the rate of pulses per second and the time of exposure to the electromagnetic field. The rate of pulses was 3/s (1.7) in our study compared to 5/s (1.6) in the previous study. The times of exposure were 20 and 5 min, respectively. The total number of pulses per treatment was 3600 in our study compared to 1500 in the other one, thus providing more energy on the surface of the exposed wound.

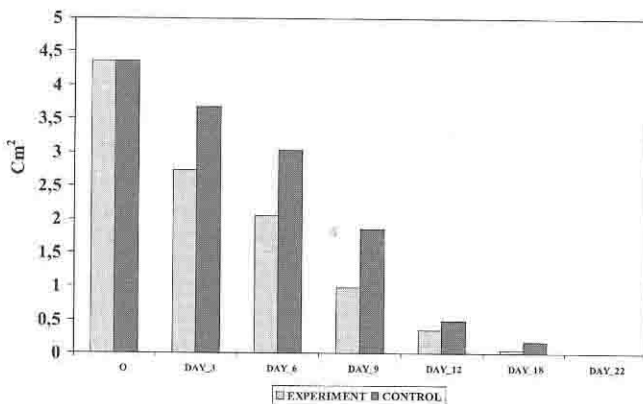


Fig. 2. Average wound area versus time for PEFM (experiment) and control groups.






Fig. 3. **a:** *Left:* Day 3 Control group. Multiple polymorphonuclear leucocytes and immature granulation tissue covers the wound area (Stage 1). *Right:* Day 3 Experimental group. Granulation tissue with newly formed capillaries, immature fibroblasts, and polymorphonuclear neutrophils (Stage 2). **b:** *Left:* Day 9 Control group. Mature granulation tissue with well-developed capillary network and relatively mature fibroblasts (Stage 3). *Right:* Day 9 Experimental group. The capillary network is mature and the fibroblasts are flattened and surrounded by collagen fibers. Re-epithelization has commenced (Stage 4). **c:** *Left:* Day 18 Control group. There is an immature squamous epithelial layer. Underneath, mature fibroblasts and bundles of collagen are noted (Stage 5). *Right:* Day 18 Experimental group. Advanced stage of healing is observed, mature epidermis and the underline fibrous connective tissue are noted (Stage 6). [The color figure for this article is available online at [www.interscience.wiley.com](http://www.interscience.wiley.com)]

According to our findings, a statistically significant acceleration of wound healing was noticed for the first 9 days in the animals exposed to PEMF. This was verified by planimetry and histology examination. The main histological evidences indicating increased healing rate in the PEMF treatment group, during this time period are the appearance from day 3 of a loose connective tissue, newly formed capillaries, increased re-epithelization, and better structure of collagen fibers.

Our data also suggest that in the time period from day 12 to 22 (complete healing of all the animals),

although no statistically significant acceleration of wound healing was noticed between the two groups, histopathology verified that healing process still predominated significantly in the PEMF group at every day of estimation (Fig. 3). Furthermore, the majority of EG had completed the healing process by day 18 in comparison to the CG, which was completed by day 22 (Table 1). Although the total time needed for complete re-epithelialization was less in the experimental group, no statistically significant difference was noticed from 12th to 22nd day (Table 1).

Initial acceleration of wound healing with a non-invasive method, such as PEMF, may be important in reducing bacteria accumulation, stimulating growth factors, cytokine production, and reducing early inflammation, thus creating an appropriate environment to facilitate tissue regeneration [Vodovnic and Karba, 1992; Aaron and Ciombor, 1993; Aaron et al., 2004].

In conclusion, according to our findings, short duration PEMF seem to facilitate and improve the quality of skin wound healing in our rat model. Nevertheless, further studies are needed to define the optimal characteristics of the PEMFs, in order to ensure a faster and more effective wound healing process.

## ACKNOWLEDGMENTS

The Authors thank Dr. Panayotis Pappas for the donation of the PAPIMI device for research purposes. ELPEN Pharma supported acquisition of the research animals. Also, the authors thank Panayotis Lekkas and Antonios Avdikos for the technical support and for taking care of the animals.

## REFERENCES

- Aaron RK, Ciombor DM. 1993. Therapeutic effects of electromagnetic fields in stimulation of connective tissue repair. *J Cell Biochem* 52(1):42–46.
- Agren MS, Engle MA, Mertz PM. 1994. Collagenase during burn wound healing: Influence of a hydrogel dressing and pulsed electrical stimulation. *Plast Reconstr Surg* 94:518–524.
- Albinucci C, Garcia JB, Palmi M, Sgaragli G, Benocci A, Meini A, Pessina F, Rossi C, Bonechi C, Pessina GP. 2003a. The effect of strong static magnetic field on lymphocytes. *Bioelectromagnetics* 24(2):109–117.
- Albinucci C, Garcia JB, Palmi M, Sgaragli G, Benocci A, Meini A, Pessina F, Rossi C, Bonechi C, Pessina GP. 2003b. The effect of exposure to high flux density static and pulsed magnetic fields on lymphocyte function. *Bioelectromagnetics* 24(3):373–379.
- Bassett CA. 1993. Beneficial effects of electromagnetic fields. *J Cell Biochem* 51(4):387–393.
- Blackman CF, Benane SG, Elder JA, House DE, Lampe JA, Faulk JM. 1980. Induction of calcium - ion efflux from brain tissue by radio frequency radiation: Effect of sample number and modulation frequency on the power density window. *Bioelectromagnetics* 1:35–43.
- Carafoli E. 2004. The ambivalent nature of calcium signal. *J Endocrinol Invest* 27 (6 suppl):134–136.
- Han L, Lin H, Head M, Blank M, Goodman R. 1998. Application of magnetic fields-induced heat shock protein 70 for presurgical cytoprotection. *J Cell Biochem*: 78:371–379.
- Ikehara T, Park KH, Yamaguchi H, Hosokawa K, Houchi H, Azuma M, Minakuchi K, Hashimoto H, Kitamura M, Kinouchi Y, Yoshizaki K, Miyamoto H. 2002. Effects of time varying strong magnetic field on release of cytosolic free Ca<sup>2+</sup> from intracellular stores in cultured bovine adrenal chromaffin cells. *Bioelectromagnetics* 23(7):505–515.
- Islamov BI, Balabanova RM, Funticov VA, Gotovskii YV, Meizerov EE. 2002. Effect of bioresonance therapy on antioxidant system in lymphocytes in patients with rheumatoid arthritis. *Bull Exp Biol Med* 134(3):248–250.
- Lander M. 1997. An essential role of free radicals and derived species in signal transduction. *FASEB J* 11:118–124.
- Macias MY, Battocletti JH, Sutton CH, Pintar FA, Maiman DJ. 2000. Directed and enhanced neurite growth with pulsed electromagnetic field stimulation. *Bioelectromagnetics* 21(4):272–286.
- Milgram J, Shahar R, Levin-Harrus T, Kass P. 2004. The effect of short high, intensity magnetic field pulses on the healing of skin wounds in rat. *Bioelectromagnetics* 25:271–277.
- Murabayashi S, Yoshikawa A, Mitamura Y. 2004. Functional modulation of activated lymphocytes by time-varying magnetic fields. *Ther Apher Dial* 8(3):206–211.
- Ottani V, De Pasquale V, Govoni P, Franchi M, Zaniol P, Ruggeri A. 1988. Effects of pulsed extremely-low frequency magnetic fields on skin wounds in the rat. *Bioelectromagnetics* 9:53–62.
- Patino O, Grana D, Bolgiani A, Prezzavento G, Merlo A. 1996. Effect of magnetic fields on skin wound healing. *Exp study Med (B Aires)* 56(1):41–44.
- Reiter RJ. 1993. Static and extremely low frequency electromagnetic field exposure: Reported effects on the circadian production of melatonin. *J Cell Biochem* 51(4):394–403.
- Robotti E, Zimpler AG, Kenna D, Grossman JA. 1999. The effect of pulsed electromagnetic fields on flexor tendon healing in chickens. *J Hand Surg [Br]* 24(1):56–58.
- Ryaby JT. 1998. Clinical effects of electromagnetic and electric fields on fracture healing. *Clin Orthop Relat Res* 355 Suppl:S205–S215.
- Scaiano JC, Monhat N, Cozens FI, Mc Lean J, Thansandote A. 1994. Application of the radical pair mechanism to free radicals in organised systems: Can the effects of 60 Hz are predicted from studies under static fields? *Bioelectromagnetics* 15:549–554.
- Simko M, Richard D, Kriehuber R, Weiss DG. 2001. Micronucleus induction in Syrian hamster embryo cells following exposure to 50 Hz magnetic fields, benzo [a] pyrene TPA in vitro. *Mutat Res* 495(1–2):43–50.
- Stonati L, Testa A, Villani P, Marino C, Lovisolo GA, Conti D, Russo F, Fresegna AM, Cordelli E. 2004. Absence of genotoxicity in human blood cells exposed to 50 Hz magnetic fields as assessed by comet assay, chromosome aberration, micronucleus, and sister chromatid exchange analyses. *Bioelectromagnetics* 25(1):41–48.
- Tao Q, Henderson A. 1999. EMF induces differentiation in HL-60 cells. *J Cell Biochem* 1; 73(2):212–217.
- Tofani S, Barone D, Cintorino M, De Santi MM, Ferrara A, Orlassino R, Ossola P, Peroglio F, Rolfo K, Ronchetto F. 2001. Static and ELF magnetic fields induce tumor growth inhibition and apoptosis. *Bioelectromagnetics* 22:419–428.
- Tofani S, Cintorino M, Barone D, Berardelli M, De Santi MM, Ferrara A, Orlassino R, Ossola P, Rolfo K, Tripodi SA, Tosi P. 2002. Increased mouse survival, tumor growth inhibition and decreased immunoreactive P53 after exposure to magnetic fields. *Bioelectromagnetics* 23:230–238.
- Vodovnic L, Karba R. 1992. Treatment of chronic wounds by means of electric and electromagnetic fields. Part 1. Literature review. *Med Biol Eng Comput* 30(3):257–266.
- Walker JL, Evans JM, Resing P, Guarnieri S, Meade P, Siskin BS. 1994. Enhancement of functional recovery following a crush lesion to the rat sciatic nerve by exposure to pulsed electromagnetic fields. *Exp Neurol* 125(2):302–305.

- Walleczek J. 1995. Magnetokinetics effects on radical pairs: A paradigm for magnetic field interactions with biological systems at lower thermal energy. *J And Chemother* 250:395–420.
- Walleczek J, Liburdy RP. 1990. Non thermal 60 Hz sinusoidal magnetic-field exposure enhances  $\text{Ca}^{2+}$  uptake in rat thymocytes dependence of mitogen activation. *FEBS Lett* 271: 157–160.
- Westerhoff HV, Helgerson SL, Theg SM, Van Koster O, Wikstrom M, Skulachev VP, Dancshary Z. 1983. The preseth state of the chemiosmotic theory. *Acta Biochim Biophys Acad Sci Hung* 18(3–4):129–149.