

## SPECIAL MEDICAL ISSUE

### SPECIAL POINTS:

- Papimi was in World's invent or fair in Geneva, 2007
- New Studies about infertility made in Budapest. (soon...)
- Greek Papimi congress in Athens. (...soon)



Papimi: Under world patents:

PCT WO 1994/01176  
23 National Patents  
with classification  
A61N2/00 - Magnetotherapy Medical Device.

PCT WO 2005/1496  
A1  
31 National Patents  
with classification  
G01R 33/28 - Nuclear Magnetic Resonance Generator Device.

**U.S.A. patent number: 5556418**  
**U.S.A. patent number: 7151372 B2**  
(Also, patented in all Developed and Major Countries - Russia and China included)

EN ISO 9001:2000,  
EN ISO 13485:2003  
and MDD 93/42/EEC  
Annex II by TÜV  
NORD - Notified Body,  
Germany for CE 0044  
European Approval for  
Medical Use

**+ info!**



# PAPIMI<sup>®</sup>

IMPACT NEWS ENG

05/05/2007

## DENTAL BONE RE-GROWTH CASE

**BONE REGENERATION CASE.**  
**CASO DE REGENERACION DE HUESO.**  
**Osteonecrosis**

Dra. López Peral  
Laurent Schidler  
23/01/2007

Paciente 44 años, con antecedentes de Carcinoma de pecho, recidiva bilateral en mama izquierda, metástasis a pulmones y ganglionar, con osteonecrosis en mandíbula por implantes odontológicos.

Patient 44 years old, with metastasised breast carcinoma recurrence in left breast, lung and lymphnodes filiations, severe necrosis of mandibles bones due to older implants.

History: First diagnostic was Carcinoma in situ in 1996 in right breast. She achieved operation and radiotherapy during 1997, and went to control every 6 months at Oncological clinic in Spain, until severe recurrence in left breast of her disease (3 tumours, 3 cm, 1cm, 1 cm) was diagnosed in 2001, including lung and lymphnodes metastasis, certified by P.E.T., NMR and Biopsy.

She began Papimi treatment in 2004, with an average of 20 monthly sessions, 18 minutes each one, in order to treat her breast, not her teeth.

In July 2005, the X-ray (see ref.1) shows important bone necrosis in several zones.

Historia: Paciente diagnosticada en 1996 por primera vez de carcinoma in situ en mama derecha. Se realiza operación con tumorectomía y radioterapia a principios de 1997. Los controles semestrales son negativos. En 2001, se diagnostica una recurrencia multifocal en la mama izquierda (3 tumores de 3 cm, 1cm y 1 cm c/u.), con metástasis a pulmones y ganglionares. Diagnostico confirmado mediante P.E.T., R.M.N., y biopsia.

Inicia tratamiento de Papimi 05/2004, con una media de 20 sesiones mensuales, 18 minutos c/u. para tratar su dolencia primaria.

En Julio 2005, realiza la prueba radiológica (nr. 1), donde se observan distintas zonas de necrosis.

In November 2006, patient went to dentist with her X-rays, and she was told this was a bone necrosis and the only solution was surgery, since bone cannot be regenerated.

Patient began with Papimi treatment in the mandible zone and January 2007, control X-ray was done, showing the regression of necrosis in some places, and complete healing of lesion in other zones.

At the date of today, this patient in complete regression, with all blood values in normal ranges. She did not follow any Oncological allopathic treatment since her recurrence.

En noviembre del 2006, la paciente visita a su dentista presentando la radiografía Rx1. Este le informa que la única solución es la cirugía, con posterior prótesis, ya que los huesos no pueden regenerarse.

La paciente inicia tratamientos Papimi en la zona mandibular, y en Enero 2007, los rayos-X de control (Rx2) reflejan una importante regresión de la necrosis previamente evidenciada en algunas zonas, regresión completa en otras.

A la fecha de hoy, dicha paciente no se ha operado, ni ha seguido ningún tratamiento oncológico alopatóico para su enfermedad cancerosa. Se encuentra en remisión completa, todos sus parámetros bioquímicos se encuentran dentro de los rangos normales.

PAPIMI MANAGEMENT COMPANY  
C/ Hilera Esq. B. Coris -Edf. Formatik  
29007 MALAGA— SPAIN

Tel.: + 34 609 51 38 88 - FAX: + 34 95 261 33 04  
info@papimi.tv  
www.papimi.gr - www.papimi.tv

SPECIAL MEDICAL  
ISSUE



**PAPIMI**<sup>®</sup>

IMPACT NEWS ENG

05/05/2007

## WORLDWIDE MEDICAL ADVANCE



Papimi: Under world patents:

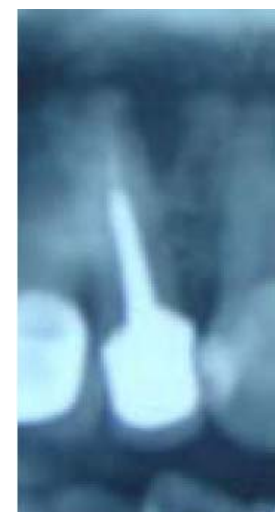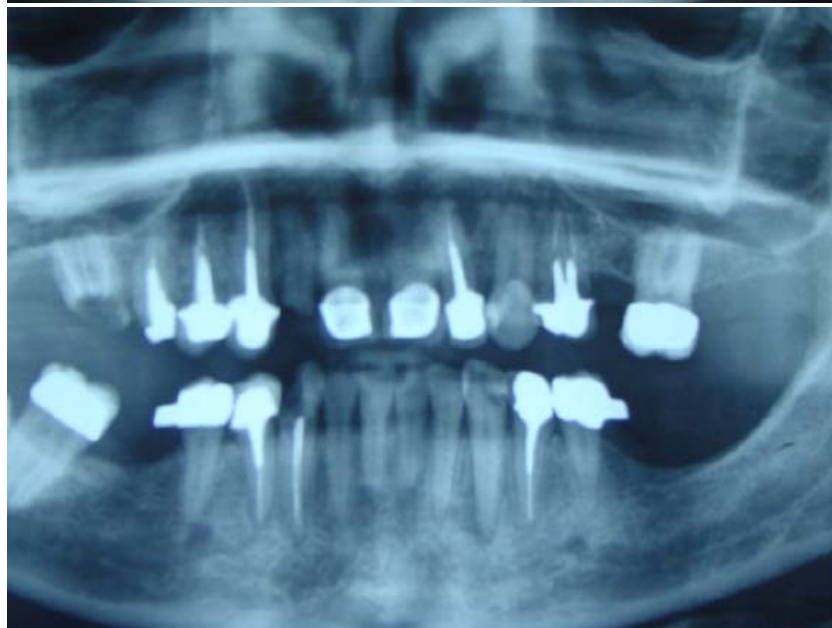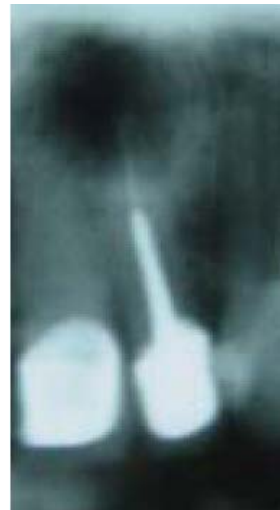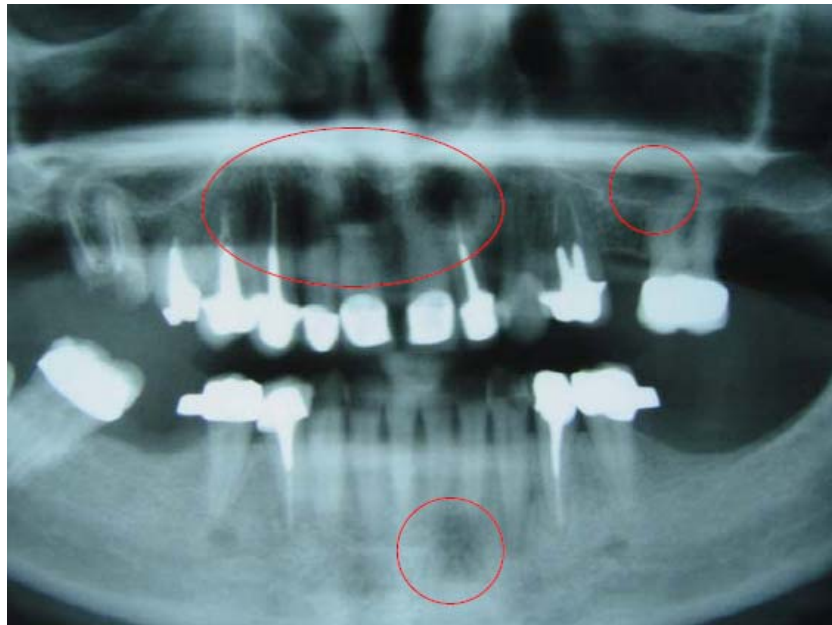
PCT WO 1994/01176  
23 National Patents  
with classification  
A61N2/00 - Magnetotherapy Medical Device.

PCT WO 2005/1496  
A1  
31 National Patents  
with classification  
G01R 33/28 - Nuclear Magnetic Resonance Generator Device.

**U.S.A. patent number: 5556418**

**U.S.A. patent number : 7151372 B2**  
(Also, patented in all Developed and Major Countries - Russia and China included)

EN ISO 9001:2000,  
EN ISO 13485:2003  
and MDD 93/42/EEC  
Annex II by TÜV  
NORD - Notified Body,  
Germany for CE 0044  
European Approval for  
Medical Use



Some teeth were opened by the dentist on the 30th. April 2007, confirming the X-Rays findings by direct observation. The heavy Operation has been suspended. Bone has been completely recovered. More X-rays to come in future. *Se han abierto algunas endodancias el día 30/04, confirmándose la reconstrucción ósea.*

**+ info!**

PAPIMI MANAGEMENT COMPANY  
C/ Hilera Esq. B. Coris -Edf. Formatik  
29007 MALAGA— SPAIN

Tel.: + 34 609 51 38 88 - FAX: + 34 95 261 33 04  
info@papimi.tv  
www.papimi.gr - www.papimi.tv